

# Unguarded Tricuspid Orifice with Congenitally Corrected Transposition of the Great Arteries and Aortic Atresia- A Highly Unusual Case

Carolyn Puegge<sup>a</sup>, Isabell Altmann<sup>a</sup> and Michael Weidenbach<sup>a\*</sup>

<sup>a</sup> Department of Pediatric Cardiology, Heart Center Leipzig, University Leipzig, Leipzig, Germany.

## Authors' contributions

*This work was carried out in collaboration among all authors. All authors read and approved the final manuscript.*

## Article Information

DOI: 10.9734/CA/2021/v10i430181

### Editor(s):

- (1) Prof. Jagadeesh Kalavakunta, Western Michigan University, USA.  
(2) Prof. Francesco Pelliccia, University La Sapienza, Italy.

### Reviewers:

- (1) Damayanti Agrawal, Apex Hospital, India.  
(2) Shreyans Singhvi, Smt NHL Municipal Medical College and SVP Hospital, India.  
(3) Sanjeev Bhat, SSH (Super Speciality Hospital Government Medical College), India.  
Complete Peer review History, details of the editor(s), Reviewers and additional Reviewers are available here:  
<https://www.sdiarticle5.com/review-history/78226>

## Case Study

**Received 06 October 2021**  
**Accepted 12 December 2021**  
**Published 15 December 2021**

## ABSTRACT

Unguarded tricuspid orifice is a very rare anomaly. It is characterised by the absence of one or more of the tricuspid valve leaflets resulting in severe tricuspid regurgitation and right heart failure. It is rarely an isolated anomaly but more often associated with pulmonary atresia and intact ventricular septum. When the ventricles are inverted however, the result of outflow tract obliteration is not pulmonary atresia, but aortic atresia. This anomaly has been described in the literature in only 2 cases so far. We present a case of a neonate with unguarded tricuspid orifice with absence of all tricuspid leaflets, congenitally corrected transposition of the great arteries and aortic atresia. The severe tricuspid regurgitation and right ventricular enlargement would have required a Norwood-like procedure combined with a right ventricular plication. Due to the complexity of this lesion no surgical therapy was attempted in consent with the parents.

**Keywords:** *Unguarded tricuspid orifice; congenitally corrected transposition of the great arteries; aortic atresia; pulmonary atresia with intact ventricular septum.*

\*Corresponding author: E-mail: michael.weidenbach@medizin.uni-leipzig.de, weidenbach@gmx.net;

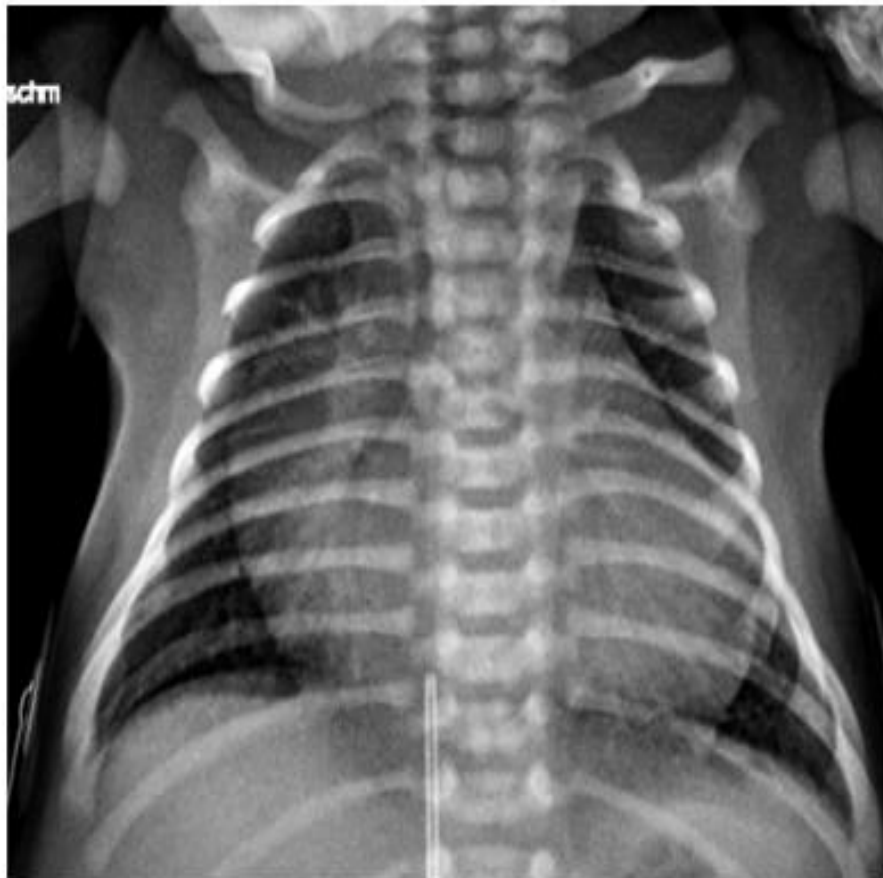## 1. INTRODUCTION

An unguarded tricuspid orifice (UTO) is characterised by the absence of one or more of the tricuspid valve (TV) leaflets, the papillary muscles and chordae tendineae, while the fibrous ring is present at the atrioventricular junction [1]. The unguarded orifice leads to severe regurgitation. This anomaly was first described in 1938 by Klein [2] and since then precise descriptions of coexisting cardiac defects have been published. The most common associated lesion is pulmonary atresia with intact ventricular septum [3]. We describe a case of a neonate with congenital corrected transposition (ccTGA) and hence a left sided subaortic right ventricle (RV) with UTO.

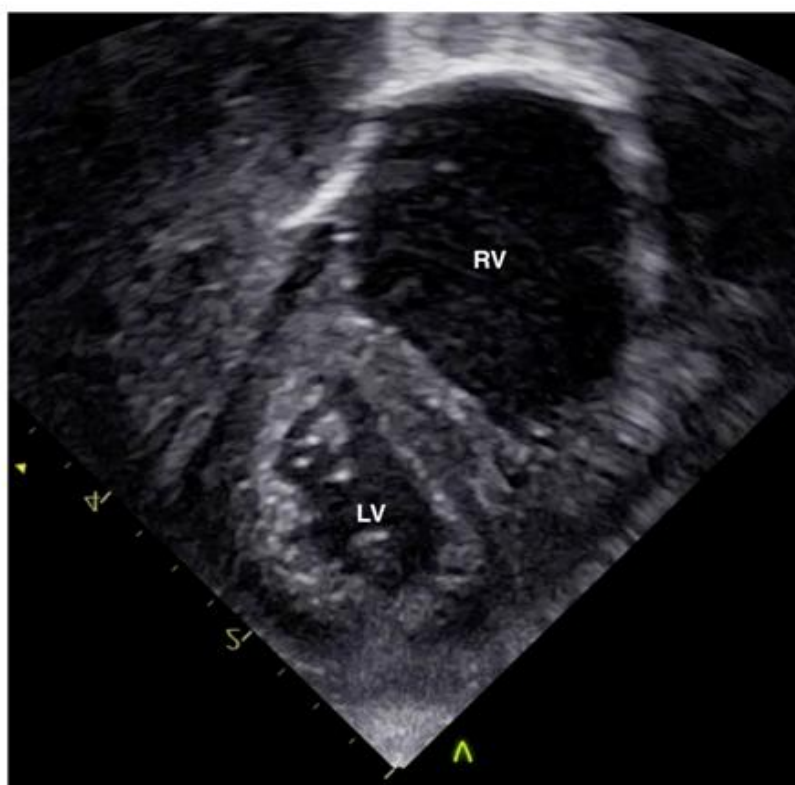
## 2. CLINICAL SUMMARY

A full-term male neonate was referred to our clinic for further diagnostic workup. Prenatal examination diagnosed aortic atresia while the other aspects of the lesion were misinterpreted as mitral regurgitation. After vaginal delivery the

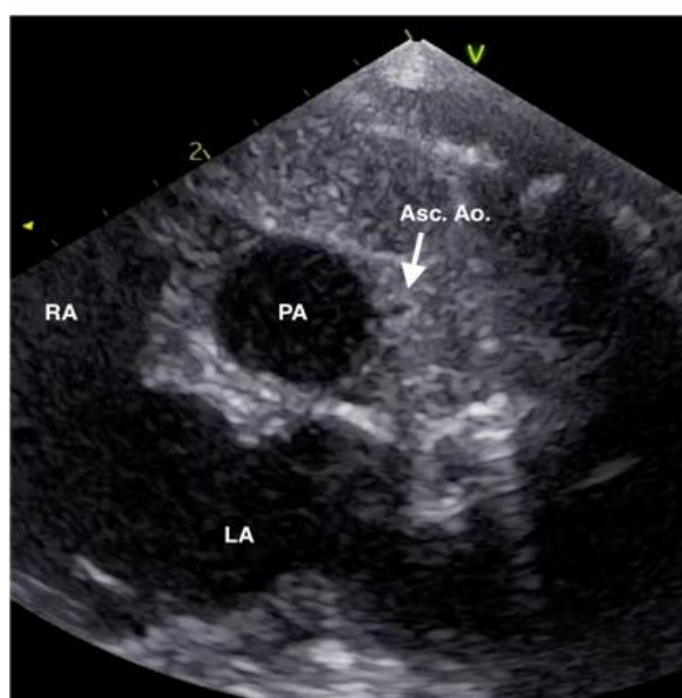child adopted well with mild tachypnea but stable circulation and sufficient oxygenation on room air. The duct was kept open with prostaglandins. Chest X-ray showed a significant cardiomegaly (Fig.1). Postnatal echocardiography demonstrated a congenitally corrected transposition of the great arteries with aortic valve atresia and hypoplastic ascending aorta (Fig. 2-4 and video 1, 2). There was absence of all leaflets of the tricuspid valve by echocardiography (Fig. 5 and video 3). The fibrous ring was enlarged with a diameter of 17 mm. There was a 'to and fro' flow between the left atrium and the RV (video 4). The latter was dilated with myocardial thinning. A large atrial septal defect and a persistent arterial duct maintained the circulation. Left ventricular function was adequate. The outflow tract appeared narrowed, though without overt stenosis (Fig. 6). Prognosis was considered very poor. In consent with both parents palliative care therefore was initiated and the child died at the age of 6 days after termination of the prostaglandins.



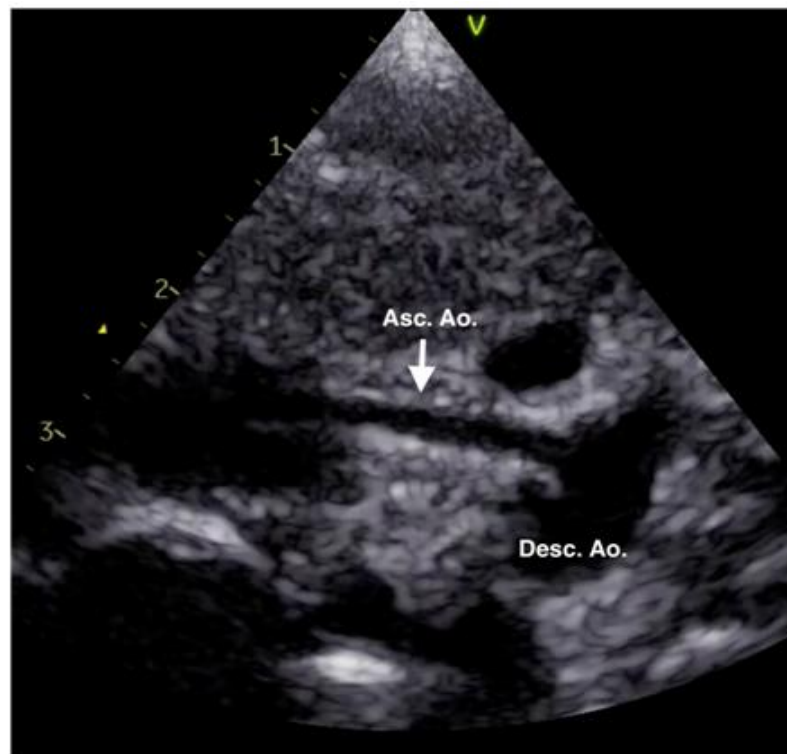
**Fig. 1. Chest X-ray demonstrating cardiomegaly**



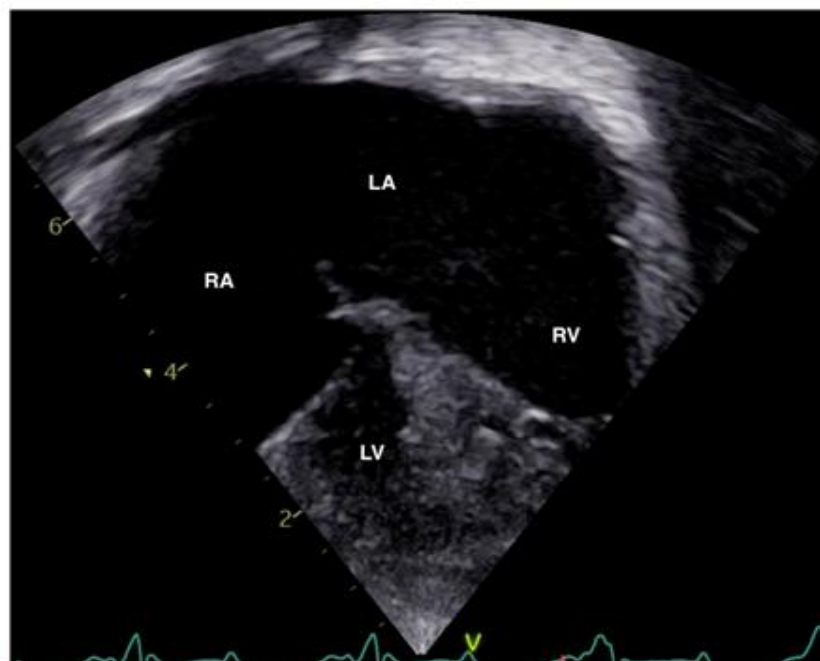**Fig. 2.** Subcostal short axis view with the left ventricle and right ventricle inverted. LV-left ventricle; RV-right ventricle



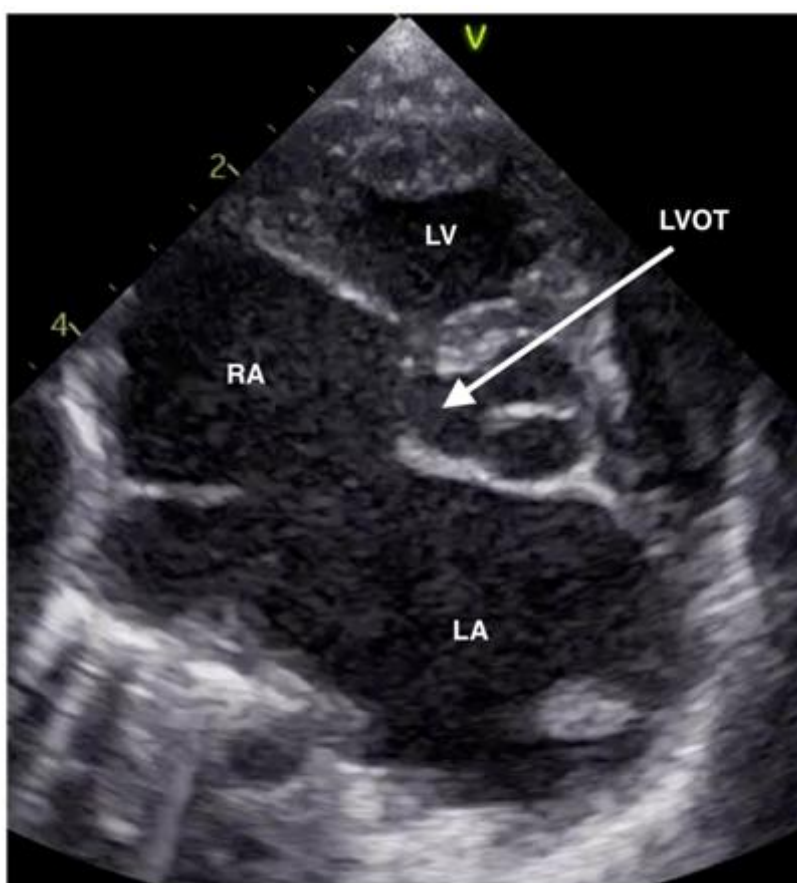
**Fig. 3.** High parasternal short axis view showing the hypoplastic ascending aorta to the left of the pulmonary artery. Asc. Ao.-ascending aorta; PA-pulmonary artery; LA-left atrium; RA- right atrium



**Fig. 4.** Suprasternal view showing the hypoplastic ascending aorta. Asc. Ao.-ascending aorta; Desc. Ao.-descending aorta



**Fig. 5.** Apical four chamber view showing the unguarded tricuspid orifice with dilated right ventricle on the left side of the patient. The left ventricle is characterised by the absence of a moderator band and lack of septal attachments of a bicuspid valve. LV-left ventricle; RV-right ventricle; LA-left atrium; RA- right atrium



**Fig. 6. Parasternal short axis view showing the narrow left ventricular outflow tract. LVOT-left ventricular outflow tract; LV-left ventricle; LA-left atrium; RA- right atrium**

### 3. DISCUSSION

The association of unguarded tricuspid orifice with pulmonary atresia and intact ventricular septum is well known, albeit very rare [3]. Prognosis is poor and patients surviving the neonatal period undergo the Fontan pathway [4]. If a profound dilation of the right ventricle is present, plication of the RV prior to Fontan procedure has been described in cases of isolated UTO [5].

Clinical presentation of neonates with pulmonary atresia and intact ventricular septum and unguarded tricuspid orifice may have much in common with cases of Ebstein's malformation and distinguishing between those two entities by echocardiography can be challenging, especially in cases with partial agenesis of valvular tissue. Anderson et al. reviewed cases of Ebstein's malformation and UTO with associated dilation of the RV and found the difference between those two lesions by examining the mural leaflet of the tricuspid valve [6]. The latter is absent in patients

with UTO but displaced in association with Ebstein's malformation. Agenesis of the tricuspid valvular tissue leads to unrestricted communication between the right atrium and ventricle resulting in a 'to and fro' flow across the atrioventricular junction [7].

Unguarded tricuspid orifice in ccTGA with atresia of the RVOT to the best of our knowledge has been described in only two cases in the literature so far [8, 9]. In contrast to our patient where all three leaflets were absent, in both previously described cases only the septal leaflet was absent. Both patients died due to intractable heart failure. In patients with ccTGA the RV is the systemic ventricle and thus atresia of the RVOT does not result in pulmonary, but aortic atresia. The aortic atresia and very hypoplastic ascending aorta would necessitate a Norwood-like procedure like in patients with hypoplastic left heart syndrome. In addition, the dilated RV probably would have required plication. Given the high risk of each of these procedures the risk in a combined approach was deemed as very

high and a palliative approach was chosen in consent with the parents. A post mortem was denied by the parents.

#### 4. CONCLUSION

Unguarded tricuspid orifice is most often associated with pulmonary atresia and intact ventricular septum. Prognosis is worse than in PA-IVS alone [3]. In ccTGA however atresia of the RVOT results in aortic atresia making surgical correction even more complicated. Only three patients with this lesion have been described so far (including our case) with no survivor.

#### CONSENT

As per international standard, parental written consent has been collected and preserved by the author(s).

#### ETHICAL APPROVAL

As per international standard or university standard written ethical approval has been collected and preserved by the author(s).

#### COMPETING INTERESTS

Authors have declared that no competing interests exist.

#### REFERENCES

1. Kanjuh VI, Stevenson JE, Amplatz K, Edwards JE. Congenitally Unguarded Tricuspid Orifice with coexistent Pulmonary Atresia. *Circulation*. 1964;30:911-917.
2. Klein H. Über einen seltenen Fall von Herzmißbildung mit rudimentärer Entwicklung des rechten Ventrikels und

- Defekt der Tricuspidalklappen. *Virchows Archiv*. 1938;301(1):1-16.
3. Muñoz Castellanos L, Salinas CH, Kuri Nivón M, García Arenal F. Ausencia de la válvula tricúspide. Informe de un caso. *Arch Inst Cardiol Mex*. 1992;62(1):61-67.
4. Hirota M, Kawada M, Ishino K, Sano S. Staged Fontan's operation for unguarded tricuspid orifice with pulmonary atresia. *Eur J Cardiothorac Surg*. 2008;34(5):1111-1112.
5. Kaneko Y, Takeda T, Yoda H, et al. Right ventricular plication in a neonate with an unguarded tricuspid valvar orifice. *Ann Thorac Surg*. 2009;87(1):305-307.
6. Anderson RH, Silverman NH, Zuberbuhler JR. Congenitally unguarded tricuspid orifice: its differentiation from Ebstein's malformation in association with pulmonary atresia and intact ventricular septum. *Pediatr Cardiol*. 1990;11(2):86-90.
7. Kumar Vikraman S, Chandra V, Balakrishnan B, Jaiman S, Batra M, Kannoly G. Unguarded tricuspid orifice---a rare cause of fetal right atrial dilatation with characteristic color doppler sign: Case report with review of literature. *J Clin Ultrasound*. 2017;45(6):370-374.
8. Freund M, Magener A, Schmidt K. Discordant atrioventricular and ventriculoarterial connections with partially unguarded left-sided atrioventricular orifice and aortic atresia. *Cardiol Young* 1997, 7(4), 450-453.
9. Williams JL, Lockhart JL, Miller SG, Barker PCA, Campbell MJ. Left-sided congenitally unguarded tricuspid valve with congenitally corrected transposition of the great arteries: A rare diagnosis confirmed by three-dimensional echocardiography. *Echocardiography*. 2020 Jul;37(7):1101-1104.

© 2021 Puegge et al.; This is an Open Access article distributed under the terms of the Creative Commons Attribution License (<http://creativecommons.org/licenses/by/4.0>), which permits unrestricted use, distribution, and reproduction in any medium, provided the original work is properly cited.

Peer-review history:

The peer review history for this paper can be accessed here:  
<https://www.sdiarticle5.com/review-history/78226>